

Retroperitoneal Varices Presenting as an Adrenal Pseudotumor in a Cirrhotic Patient

Anil S. Paramesh, MD; Ryan Meiners, MD; Ralph B. Fairchild, MD; Shekar Sane, MD; Magdalene George, PhD; David H. Van Thiel, MD

ABSTRACT

Herein is reported a case of a putative tumor of the left adrenal gland found incidentally during the workup of a cirrhotic patient with portal hypertension. This mass manifested vascular enhancement and other features of an adenoma both on computed tomography (CT) and magnetic resonance imaging (MRI) scans. Additional workup revealed elevated salivary cortisol and plasma aldosterone levels. A proposed biopsy of this mass was deferred because of an episode of variceal bleeding that required placement of a transjugular intrahepatic portosystemic shunt (TIPS). Post TIPS placement, repeat CT and MRI scans showed that the mass had disappeared, indicating that this pseudotumor was, in fact, a knot of peri-adrenal varices, which was now decompressed.

In this report, the anatomic and pathologic basis of peri-adrenal varices in a patient with portal hypertension is discussed, as well as the ability of current imaging studies at establishing this diagnosis. Liver disease may cause abnormalities in endocrine function, which make this diagnosis difficult.

CASE REPORT

A 69-year-old white male was transferred from a peripheral medical center to the Hepatology service because of variceal bleeding. He presented to a local emergency department vomiting blood. He gave a history of nausea and black stools for the preceding 2 days. He underwent an esophago-gastro-duodenoscopy (EGD), which revealed esophageal and gastric varices with por-

tal hypertensive gastropathy. The esophageal varices ranged from Grade II to III, and showed evidence of recent bleeding. The esophageal varices were banded, and the patient was transferred for further treatment.

He denied any prior knowledge of liver disease. He complained of lethargy over the past few months and some difficulty sleeping at night. He had lost over 30 lbs. in the preceding 3 months. He had a history of a gastric ulcer 8 years earlier. He denied taking any aspirin or non-steroidal anti-inflammatory medications. He had had no previous blood transfusions. He had never used alcohol, tobacco, or recreational drugs. He had no tattoos. He lived on a farm with his disabled wife.

On physical examination, he was 6'1" and weighed 212 lbs. He was anicteric, and had both splenomegaly and ascites. Laboratory tests showed a total bilirubin of 0.8 mg/dl, alanine transaminase (ALT) of 48 U/L (normal 21-72 U/L), aspartate transaminase (AST) of 43 U/L (normal 14-50 U/L), alkaline phosphatase of 106 U/L (normal 38-126 U/L), albumin of 2.6 gm/dl (normal 3.5-5 gm/dl), creatinine of 0.7 mg/dl, hematocrit of 39.3, platelet count of 113,000/ml, prothrombin time of 11.6 seconds, with an International Normalized Ratio (INR) of 1.1.

Further bloodwork revealed a negative hepatitis virus panel (Hepatitis A, B, and C); normal alpha-1 antitrypsin levels with an MM phenotype and negative antimitochondrial antibody (AMA) and antinuclear antibody (ANA) tests. A liver biopsy documented cirrhosis with non-alcoholic steatohepatitis (NASH).

He underwent a contrast-enhanced computed tomography (CT) scan of his abdomen, which revealed a cirrhotic liver with patent vasculature, splenomegaly, and ascites. There were no masses suggestive of tumor in his liver. The liver measured approximately 800 cc in volume (normal 1400-2000 cc) and the spleen measured approximately 600 cc (normal <400 cc). Extensive esophageal and gastric varices were noted. A 3.5 x 2.2 cm mass involving the left adrenal gland was identified,

Authors are with St. Luke's Medical Center, Aurora Health Care, Milwaukee, Wis. Doctors Paramesh and Fairchild are with the Division of Abdominal Transplant Surgery, Doctors Meiners and Sane are with the Division of Interventional Radiology, and Dr George and Doctor Van Thiel are with the Division of Liver Diseases. Please address correspondence to: Anil S. Paramesh, MD, Division of Abdominal Transplant Surgery, St. Luke's Medical Center, Aurora Health Care, 2801 W Oklahoma Ave, Ste 511, Milwaukee, WI 53215; phone 414.649.2608; fax 414.646.5414; e-mail anil.paramesh@aurora.org.

which showed arterial enhancement consistent with a tumor. A subsequent magnetic resonance imaging (MRI) with chemical shift imaging, T2 turbo spin echo and dynamic contrast enhanced gradient echo sequences to better characterize the adrenal mass was performed, and confirmed the CT finding (Figure 1). The adrenal mass demonstrated both arterial and portal venous phase enhancement.

An endocrine consult was obtained to evaluate this adrenal mass. Further questioning revealed a history of nephrolithiasis. There was no family history of endocrine disorders, and a review of his electrolyte studies was normal.

Additional laboratory studies included normal TSH and plasma metanephrine levels, an elevated nocturnal salivary cortisol at 6.7 nanomol/L (normal <4.3 nmol/L), an elevated upright aldosterone level at 53.6 ng/dl (normal 1.6 – 31 ng/dl), with a normal upright renin level of 2.3 ng/ml/hr (normal 0.5 – 4 ng/ml/hr). It was felt that his liver disease and recent variceal bleeding were largely responsible for these abnormalities. The endocrine consultants felt that the adrenal mass may be a non-functioning tumor, and an adrenal biopsy was suggested to rule out a malignancy.

During the period of this evaluation, he had a second episode of variceal bleeding and required additional endoscopic varix ligation. Because of his recurrent bleeding, he underwent a transjugular intrahepatic portosystemic shunt (TIPS) procedure. He did well post-procedure, and has had no recurrent variceal bleeding. Interestingly, a follow-up CT scan with contrast done 2 weeks post TIPS showed that the presumed mass within the adrenal gland had disappeared (Figure 2). Based on the sequence of events and a rereview of his imaging studies, it was felt that the “mass” represented a knot of retroperitoneal varices that overlay the adrenal gland. These varices disappeared with decompression of his portal venous system with the TIPS.

DISCUSSION

The perinephric compartment containing the adrenal gland may demonstrate pathology originating from outside its fascial planes.¹ Lymphatics, venous collaterals, and bridging perinephric septae all serve as potential conduits for the spread of retroperitoneal disease. Enlarged perirenal collaterals have been described in patients with hypervascular renal neoplasms, renal vein thrombosis, and portal hypertension. With portal hypertension, several hypotheses have been put forward to explain such varices. Retroperitoneal collateral vessels have been described that directly traverse the pos-

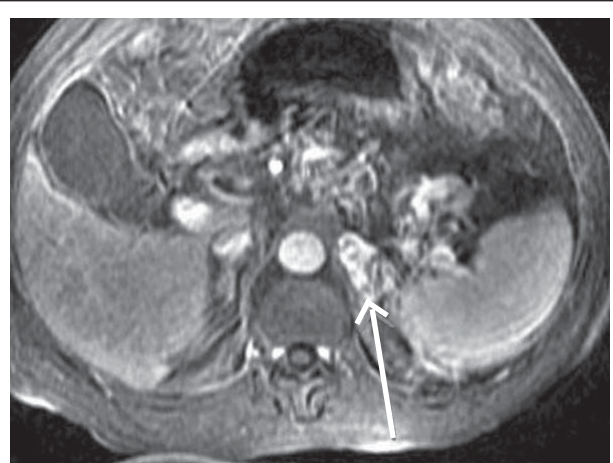


Figure 1. Contrast-enhanced MR scan of the abdomen showing enhancing mass (arrow) in the region of the left adrenal gland. The mass demonstrated characteristics of a tumor.

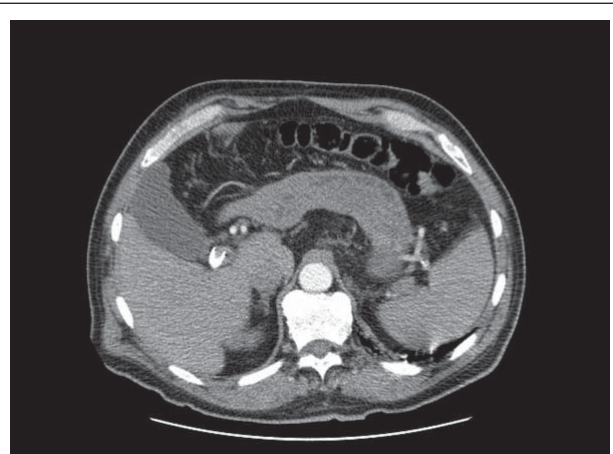


Figure 2. Contrast-enhanced CT scan of the abdomen performed 2 weeks post TIPS. The previously seen mass is no longer visualized.

terior perirenal fascia, suggesting pre-existing vascular perforations along this fascial plane. The left perinephric space is continuous with the bare area of the spleen, and the splenic vein travels within the splenorenal ligament, allowing for the development of varices here. The left inferior phrenic vein runs along the anterior wall of the left adrenal gland and joins the left adrenal vein proximal to its junction with the left renal vein. This vein may communicate with the splenic vein and serve as a collateral between the splenic and left renal vein.² Such collaterals with high flow may show enhancement with intravenous contrast, and may be difficult to distinguish from the adrenal gland on imaging studies.

In a retrospective series reported by Brady et al,² 9 patients were identified as having peri-adrenal varices

over a 2-year period using contrast-enhanced CT scans. All of these patients had known portal hypertension. These varices appeared as enhancing lesions in the expected location of the left adrenal gland. The varices were confirmed by angiography in 7 of these 9 patients, and by MRI in the remaining 2. While this finding may occasionally be seen with contrast-enhanced CT scans in patients with portal hypertension, the authors conclude that MRI may be the confirmatory test in equivocal cases.

MR imaging is continuously improving. High-contrast resolution and multiplanar imaging enables the detection and characterization of many adrenal masses.³ Combinations of MR imaging techniques usually include chemical shift imaging to identify fat content indicative of an adenoma of the adrenal, followed by subsequent T2 turbo spin echo and dynamic contrast enhanced gradient echo sequences to identify vascular and inflammatory characteristics of the tumor. This combination of sequence imaging has been reported to have a sensitivity, specificity, and accuracy of 100%, 91%, and 94%, respectively.⁴ The individual herein reported had a positive chemical shift imaging study, suggesting an adenoma, and further images demonstrated vascular enhancement suggestive of a tumor as well.

Two recent publications have examined the imaging characteristics of adrenal adenomas.^{5,6} Non-secreting adrenal adenomas are recognized in nearly 1% of individuals undergoing radiologic examinations of their abdomen. The frequency of such adenomas increases with age and can reach up to 7% in individuals aged >70 years.

Radionuclide studies can also be helpful in the differential diagnosis of adrenal masses.⁵ Increased nor-cholesterol uptake is reported in 100% of adenomas and abnormal metaiodobenzylguanidine (MIBG) activity is reported in 100% of pheochromocytomas. Had either of these studies been performed in this case, the results might have directed the differential diagnosis away from a primary adrenal pathology.

The initial endocrine evaluation of this patient's pseudomass was misleading. His history of disrupted sleep and fatigue probably contributed to his elevated salivary cortisol level, while his gastrointestinal bleeding with volume depletion, as well as the initiation of a low sodium diet may have produced his elevated aldosterone level. While this was believed to be a non-functioning tumor, a biopsy was considered to rule out a malignancy. It is perhaps somewhat fortunate that the patient did not undergo a biopsy of this mass because

the repeat variceal bleed that prompted a TIPS placement first decompressed this varix.

CONCLUSION

An adrenal pseudotumor caused by peri-adrenal varices was identified in a cirrhotic patient. While peri-adrenal varices have been previously reported on contrast-enhanced CT scans, their demonstration with MRI has not been reported previously and may yield false positive results. The picture may be further complicated by the presence of endocrine abnormalities that occur as a result of liver disease.

REFERENCES

1. Aizenstein RI, Owens C, Sabnis S, Wilbur AC, Hibbeln JF, O'Neil HK. The perinephric space and renal fascia: review of normal anatomy, pathology, and pathways of disease spread. *Crit Rev Diagn Imaging*. 1997;38(4):325-367.
2. Brady TM, Gross BH, Glazer GM, Williams DM. Adrenal pseudomasses due to varices: angiographic-CT-MRI-pathologic correlations. *Am J Roentgenology*. 1985;145(2):301-304.
3. Zimmerman GG, Debatin JF, Krestin GP. The differentiation of adrenal gland tumors: an improvement in accuracy by a combination of fat-sensitive, T2 weighted and contrast-enhanced MR sequences. (German). *Rofo:Fortschritte Gebiete Rontgenstrahlen Nuklearmedizin*. 1997;167(2):153-159.
4. Hussain HK, Korobkin M. MR imaging of the adrenal glands. *Magn Reson Imaging Clin North Am*. 2004;12(3):515-544.
5. Maurea S, Caraco C, Klain M, Mainolfi C, Salvatore M. Imaging characterization of non-hypersecreting adrenal masses. Comparison between MR and radionuclide techniques. *Q J Nucl Med*. 2004;48:188-197.
6. Zarco-Gonzalez JA, Herrera MF. Adrenal incidentaloma. *Scandinavian J Surg*. 2004;93:298-301.

Wisconsin Medical Journal

The mission of the *Wisconsin Medical Journal* is to provide a vehicle for professional communication and continuing education of Wisconsin physicians.

The *Wisconsin Medical Journal* (ISSN 1098-1861) is the official publication of the Wisconsin Medical Society and is devoted to the interests of the medical profession and health care in Wisconsin. The managing editor is responsible for overseeing the production, business operation and contents of the *Wisconsin Medical Journal*. The editorial board, chaired by the medical editor, solicits and peer reviews all scientific articles; it does not screen public health, socioeconomic or organizational articles. Although letters to the editor are reviewed by the medical editor, all signed expressions of opinion belong to the author(s) for which neither the *Wisconsin Medical Journal* nor the Society take responsibility. The *Wisconsin Medical Journal* is indexed in Index Medicus, Hospital Literature Index and Cambridge Scientific Abstracts.

For reprints of this article, contact the *Wisconsin Medical Journal* at 866.442.3800 or e-mail wmj@wismed.org.

© 2006 Wisconsin Medical Society