

# Vertebral Osteomyelitis in a Healthy Young Adult

*Nitin Jain, MD; Dhaval Patel, MD; Kurt J. Pfeifer, MD*

## ABSTRACT

A 39-year-old African American man with no significant past medical history presented to our hospital with right hand weakness and pain in both arms. He had no fever, neck pain, headache, dizziness, vision changes, or weakness in his lower extremities. Magnetic resonance imaging of the cervical spine showed extensive abnormal enhancement of the C7-T1 vertebral bodies as well as the prevertebral and epidural spaces. Open biopsy of the lesion showed inflammatory changes consistent with osteomyelitis. Culture of the biopsy specimen grew Group B Streptococcus (GBS). HIV ELISA and blood cultures were negative. The patient was treated with intravenous vancomycin for 6 weeks with complete resolution of symptoms. GBS classically affects newborns and pregnant females. However, the incidence of infection from this pathogen in nonpregnant adults is increasing. Vertebral osteomyelitis due to GBS in nonpregnant adults is exceedingly rare. To our knowledge, this is the first reported case of GBS cervical vertebral osteomyelitis in an adult without risk factors for invasive GBS infection. This case illustrates that GBS should be included in the differential diagnosis of pyogenic vertebral osteomyelitis, irrespective of immune status and predisposing factors.

## INTRODUCTION

Group B Streptococcus (GBS) infection classically affects newborns and pregnant women and is often not considered in the differential diagnosis of non-pregnant adults. Cases of invasive GBS infection in non-pregnant adults were reported as early as the 1940s, and the incidence of GBS infection in non-pregnant adults is increasing.<sup>1-5</sup> The majority of patients with invasive GBS disease have characteristics that predispose them

to infection. We report a case of GBS vertebral osteomyelitis in a previously healthy male patient.

## CASE REPORT

A 39-year-old African American man with no significant past medical history initially presented to another hospital with left-sided chest pain radiating to the left arm and neck. Myocardial infarction was ruled out by normal serial cardiac enzymes, and chest computed tomography (CT) was negative for pulmonary embolism. However, CT revealed a prevertebral C7-T1 soft tissue mass measuring 4.5 cm x 1.2 cm. He was discharged from the emergency department with plans for rapid follow-up to further investigate this lesion.

Two days later, he presented to our hospital with bilateral arm pain and right hand weakness causing difficulties with writing, grasping, and performing activities of daily living. He was not taking any medications and had no history of intravenous drug abuse. He had no fever, neck pain, headache, dizziness, vision changes, or weakness in the lower extremities. On physical examination, he was healthy appearing and in no acute distress with a temperature of 98.0° F, heart rate of 104 beats per minute, blood pressure 138/90 mmHg, and respiratory rate of 16 breaths per minute. Cardiovascular, respiratory, and abdominal examination was normal. The patient had decreased strength in the intrinsic muscles of his right hand with a mild light-touch sensory deficit in the medial part of the right hand and forearm. No tenderness was appreciated over the cervical spine. Laboratory examination at admission showed hemoglobin 14.7 g/dl, platelet count 497 X 10<sup>9</sup>/l and white blood cell count 9.9 X 10<sup>9</sup>/l with a normal differential. Erythrocyte sedimentation rate was elevated at 30 mm/hr, and HIV ELISA and blood cultures were negative. Intravenous corticosteroids were started on admission to reduce neuropathic symptoms potentially caused by spinal cord compression.

Subsequent workup included magnetic resonance imaging (MRI) of the neck (Figure 1) that showed extensive abnormal enhancement of C7-T1 vertebral

**Author Affiliations:** Department of Medicine, Medical College of Wisconsin, Milwaukee, Wis (Jain, Patel, Pfeifer).

**Corresponding Author:** Nitin Jain, MD, Department of Medicine, Medical College of Wisconsin, 8701 Watertown Plank Rd, Milwaukee, WI 53226; phone 414.456.6791; fax 414.456.6213; e-mail njain@mcw.edu.

bodies as well as the anterior prevertebral and epidural spaces. Abnormal enhancement extended into the neural foramina bilaterally at C7-T1 and on the right at T1-T2. Since 2 adjacent vertebral bodies were involved and enhancement was present, this was felt to be consistent with infection. Echocardiogram was negative for infective endocarditis, and neurosurgery was consulted for biopsy of the lesion. Open biopsy was performed and purulent fluid drained from the lesion. Culture of the fluid grew GBS. Fungal and acid-fast bacilli cultures were negative. Biopsy of the prevertebral mass showed mixed acute and chronic inflammatory changes consistent with osteomyelitis. The patient's symptoms improved significantly with surgical drainage, and he was discharged to home with 6 weeks of intravenous vancomycin, as he was allergic to penicillin. His final diagnosis was vertebral osteomyelitis due to Group B Streptococcus, and 10 months after discharge, he is doing well with no recurrence of the disease.

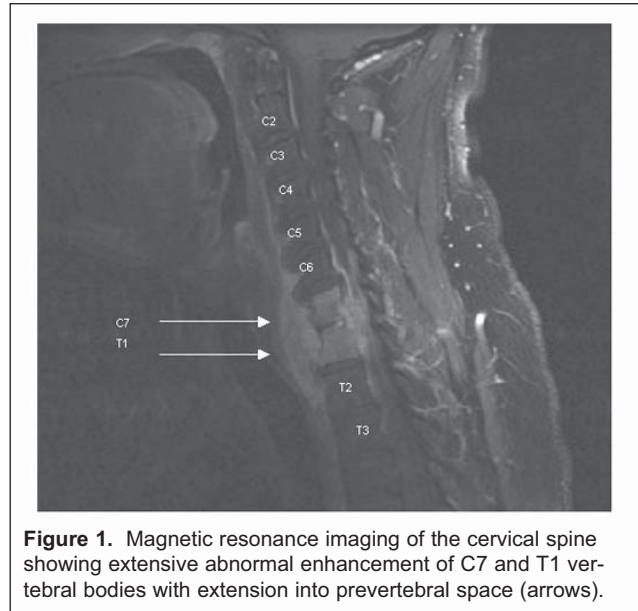
## DISCUSSION

Group B streptococcus is a major cause of sepsis and meningitis in neonates and pregnant females.<sup>2,6</sup> However, the incidence of invasive infection in nonpregnant adults is also increasing.<sup>2,3-5</sup> Population-based surveillance data from the Atlanta area in 1982 reported the incidence of invasive GBS in adults to be 2.2/100,000 and active surveillance data from 1998 showed an incidence of 6.3/100,000.<sup>3,4</sup> Thus, the incidence of invasive GBS in adults has more than doubled in the last 2 decades.

At the same time, the incidence of early-onset (<7 days of age) neonatal disease due to GBS has steadily declined from 1.8 per 1000 live births during 1990 to 0.34 per 1000 live births in 2004.<sup>7,8</sup> This decline is attributed to the universal screening of all pregnant women for GBS colonization (mandated since 2002) and widespread institution of intrapartum maternal chemoprophylaxis.<sup>9,10</sup>

Schrag et al performed an active laboratory-based surveillance from 1993-1998 in 8 different states.<sup>4</sup> An invasive infection was defined as isolation of GBS from a normally sterile site (e.g. blood or cerebrospinal fluid). Isolation of GBS from amniotic fluid, placenta, or urine alone were not included. They reported that two-thirds of all invasive infections due to GBS occurred in non-pregnant adults, and the elderly population (age >65) accounted for half of these cases.<sup>4</sup> Furthermore, mortality data from the same surveillance study showed that more than 90% of all deaths due to GBS occur in non-pregnant adults.<sup>4</sup>

The incidence of GBS is proportional to age, with an



**Figure 1.** Magnetic resonance imaging of the cervical spine showing extensive abnormal enhancement of C7 and T1 vertebral bodies with extension into prevertebral space (arrows).

incidence of 2.1/100,000 in the 18-34 year age group as compared to 21.7/100,000 in the elderly.<sup>11</sup> The African American population is also 2 times more susceptible to invasive infection than whites, and diabetes mellitus increases the risk of both soft tissue and bone GBS infections.<sup>2,3,6,11</sup>

Malignancy, particularly breast cancer, is associated with increased risk of infection, and many cases of GBS cellulitis in the lymphedematous arm of a patient with breast cancer after surgery and radiation have been reported.<sup>2,3,6</sup> Additional risk factors for invasive GBS infection include HIV, cirrhosis, decubitus ulcers, previous stroke, neurogenic bladder, and long-term care residence.<sup>2,6,12</sup>

Common clinical presentations of invasive GBS in non-pregnant adults include skin, soft tissue and bone infection, and bacteremia without an identifiable source.<sup>2,3,6</sup> These 2 clinical presentations constitute two-thirds of all cases, and most cases of osteomyelitis are in diabetic patients with foot ulcers. Other manifestations of invasive infection include pneumonia, urosepsis, meningitis, and endocarditis.

Vertebral osteomyelitis due to GBS is a rare entity. To our knowledge, only 17 such cases have been reported in the English literature.<sup>13-26</sup> Only 1 case of cervical vertebral osteomyelitis due to GBS has been reported previously.<sup>15</sup> This was in an elderly male with a history of atrial fibrillation who presented with fever and neck pain. All other cases of vertebral osteomyelitis involved the lumbar spine and most had predisposing factors.

The mainstay of treatment of GBS infection remains antibiotic therapy, and penicillin remains the drug of

choice. For penicillin-allergic patients, cephalosporins or vancomycin can be used. For deep-seated infections, such as endocarditis, aminoglycosides can be added for synergy. For localized abscesses, surgical drainage is necessary.

Given the emerging problem of GBS infection in adults, vaccination against GBS is currently undergoing early clinical studies. A recent report described a phase I trial in which healthy volunteers between age 65 and 85 years were given a GBS conjugate vaccine consisting of GBS type 5 capsular antigen and tetanus toxoid.<sup>27</sup> Adequate post-immunization levels of antibody were noted in most participants, but further studies are needed to determine if vaccination would be a cost-effective strategy in this age group.

## CONCLUSION

The incidence of invasive GBS infection is increasing in non-pregnant adults, and it typically presents as bacteremia or skin, soft tissue and bone infection. Vertebral osteomyelitis is a rare presentation of invasive infection, but GBS should be included in the differential diagnosis of pyogenic vertebral osteomyelitis, irrespective of immune status and predisposing factors.

**Acknowledgments:** Authors acknowledge the staff at St. Joseph Regional Medical Center, Milwaukee, and Dr. Nidhi Aggarwal for her help in editing the manuscript.

**Financial Disclosure:** None declared.

**Funding/Support:** None declared.

## REFERENCES

1. Rantz LA. Suppurative arthritis due to a hemolytic streptococcus of the Lancefield group B: a case report. *Ann Intern Med.* 1940;13:1744-1747.
2. Farley MM, Harvey RC, Stull T, et al. A population-based assessment of invasive disease due to group B streptococcus in nonpregnant adults. *N Engl J Med.* 1993;328:1807-1811.
3. Schwartz B, Schuchat A, Oxtoby MJ, Cochi SL, Hightower A, Broome CV. Invasive group B streptococcal disease in adults: a population-based study in metropolitan Atlanta. *JAMA.* 1991;266:1112-1114.
4. Schrag SS, Zywicki S, Farley MM, et al. Group B streptococcal disease in the era of intrapartum antibiotic prophylaxis. *N Engl J Med.* 2000;342:15-20.
5. Farley MM. Group B streptococcal infection in older patients. *Drugs Aging.* 1995;6:293-300.
6. Jackson LA, Hilsdon R, Farley MM, et al. Risk factors for group B streptococcal disease in adults. *Ann Intern Med.* 1995;123:415-420.
7. Zangwill KM, Schuchat A, Wenger JD. Group B streptococcal disease in the United States, 1990: report from a multistate active surveillance system. *MMWR CDC Surveill Summ.* 1992;41:25-32.
8. Centers for Disease Control and Prevention. Early-onset and late-onset neonatal group B streptococcal disease--United States, 1996-2004. *MMWR Morb Mortal Wkly Rep.* 2005;54:1205-1208.
9. Schrag S, Gorwitz R, Fultz-Butts K, Schuchat A. Prevention of perinatal group B streptococcal disease. Revised guidelines from CDC. *MMWR Recomm Rep.* 2002;51:1-22.
10. ACOG Committee Opinion: number 279, December 2002. Prevention of early-onset group B streptococcal disease in newborns. *Obstet Gynecol.* 2002;100:1405-1412.
11. Farley MM. Group B streptococcal disease in nonpregnant adults. *Clin Infect Dis.* 2001;33:556-561.
12. Henning KJ, Hall EL, Dwyer DM, et al. Invasive group B streptococcal disease in Maryland nursing home residents. *J Infect Dis.* 2001;183:1138-1142.
13. Chung S, Chen C, Yu W. Spinal epidural abscess caused by Group B streptococcus in a diabetic woman presenting with febrile low back pain. *Jpn J Infec Dis.* 2005;58:177-179.
14. Pozo JS, Martinez-Alfaro E, Abad L, Solera J. Vertebral Osteomyelitis Caused by Streptococcus agalactiae. *J Infect.* 2000;41:84-90.
15. Meis JF, Kullberg B, Kremer H, Verweij P. Cervical spinal epidural abscess due to group B streptococcus in a previously healthy elderly male. *Sand J Infect Dis.* 2000;32:577.
16. Mouly S, Berenbaum F, Kaplan G. Group B streptococcal vertebral osteomyelitis with bacteremia in an adult with no debilitating condition. *Scan J Infect Dis.* 1999;31:316-317.
17. Archer TP, Mangino JE, Mazzaferri EL. A woman with severe low back pain. *Hosp Pract.* 1998;33:87-90.
18. Bauer TM, Pippert H, Zimmerli W. Vertebral osteomyelitis caused by group B Streptococci (Streptococcus agalactiae) secondary to urinary tract infection. *Eur J Clin Microbiol Infect Dis.* 1997;16:244-246.
19. Ganapathy ME, Rissing JP. Group B streptococcal vertebral osteomyelitis with bacteremia. *South Med J.* 1995;88:350-351.
20. Gelfand MS, Hughey JR, Sloas DD. Group B streptococcal bacteremia associated with adenocarcinoma of the stomach. *Clin Infect Dis.* 1994;19:364.
21. Elhanan G, Raz R. Group B Streptococcal Vertebral osteomyelitis in an adult. *Infection.* 1993;21:397-399.
22. Bath PMW, Pettingale KW. Group B streptococcal osteomyelitis of the spine. *J R Soc Med.* 1990;83:183.
23. Fasano FJ Jr, Graham DR, FACP, Stauffer ES. Vertebral osteomyelitis secondary to Streptococcus agalactiae. *Clin Orthop.* 1990;256:101-104.
24. McMeekin AA, Holzman R, Desiderio D, et al. Group B streptococcal osteomyelitis in an adult. *NY State J Med.* 1987;87:466-467.
25. Gordon DM, Oster CN. Hematogenous group B streptococcal osteomyelitis in an adult. *South Med J.* 1984;77:643-645.
26. Musher DM, Thorsteinsson SB, Minuth JN, Luchi RJ. Vertebral osteomyelitis: still a diagnostic pitfall. *Arch Intern Med.* 1976;136:105-110.
27. Palazzi DL, Rench MA, Edwards MS, Baker CJ. Use of type V group B streptococcal conjugate vaccine in adults 65-85 years old. *J Infect Dis.* 2004;190:558-564.

# Wisconsin Medical Journal

The mission of the *Wisconsin Medical Journal* is to provide a vehicle for professional communication and continuing education of Wisconsin physicians.

The *Wisconsin Medical Journal* (ISSN 1098-1861) is the official publication of the Wisconsin Medical Society and is devoted to the interests of the medical profession and health care in Wisconsin. The managing editor is responsible for overseeing the production, business operation and contents of the *Wisconsin Medical Journal*. The editorial board, chaired by the medical editor, solicits and peer reviews all scientific articles; it does not screen public health, socioeconomic or organizational articles. Although letters to the editor are reviewed by the medical editor, all signed expressions of opinion belong to the author(s) for which neither the *Wisconsin Medical Journal* nor the Society take responsibility. The *Wisconsin Medical Journal* is indexed in Index Medicus, Hospital Literature Index and Cambridge Scientific Abstracts.

For reprints of this article, contact the *Wisconsin Medical Journal* at 866.442.3800 or e-mail [wmj@wismed.org](mailto:wmj@wismed.org).

© 2007 Wisconsin Medical Society