

# Penile Oleogranuloma Among Wisconsin Hmong

*Philip M. Zickerman, MD; Chirasakdi Ratanawong, MD*

## ABSTRACT

Injection of viscous or semisolid materials into the penile shaft to increase its size, to correct erectile dysfunction, and/or to satisfy a sexual partner has only been sporadically reported in Eastern and Western European and American men. However, this practice appears to be more widespread in the countries of Southeast Asia. We present 3 cases of Hmong patients seen in a urology clinic in Wausau, Wis. We describe the presentation, correction, and difficulties experienced in convincing patients to undergo adequate treatment.

## INTRODUCTION

Injection of viscous or semisolid materials into the penile shaft to increase its size, correct erectile dysfunction, and/or satisfy a sexual partner has only been sporadically reported in Eastern and Western European and American men.<sup>1-11</sup> However, this practice appears to be more widespread in the countries of Southeast Asia.<sup>12-14</sup>

Since the end of the Vietnam War, there has been an influx of Southeast Asian refugees into the United States. One such group, the Hmong, continue to arrive in the United States with particularly high concentrations in specific urban areas of California, Minnesota, Wisconsin, and North Carolina.<sup>15-19</sup> The culture of the Hmong is alien to American norms and standards, and the receiving communities struggle to deal with the educational, social, and medical needs of their new citizens.

Many communities have made recommendations and developed plans to specifically address the health needs of the Hmong. These needs include significant protein malnutrition, developmental delays, incomplete

immunizations, and high rates of tuberculosis, hepatitis B, internal parasites, gout, kidney stones, osteoporosis, and mental health symptoms.<sup>20,21</sup> We have not, however, seen any mention of the surprisingly frequent practice of penile injections to enhance sexual performance in Hmong males.

Here we describe a series of 3 Hmong patients seen in our urology clinic in Wausau, Wis. The presentation of each is described along with the difficulties experienced in convincing the patients to undergo adequate treatment.

## CASE SERIES

### *Case 1*

A 37-year-old male Hmong patient was referred for evaluation of swelling of the foreskin caused by self-injection of an unidentified substance that was purchased in Minnesota for the purposes of correcting sexual dysfunction. The patient reported an initial performance improvement, but this did not endure. Subsequently, he experienced persistent swelling of the foreskin causing occasional difficulty in urination. At presentation, the patient denied current outlet obstruction, dysuria, hematuria, or blood in his ejaculate. He had no history of prostate infection, renal stones, or genitourinary instrument examination.

Screening for sexually transmitted disease was negative. Genital examination revealed bilaterally descended testicles of normal size and consistency without mass. The epididymis and cord structure were normal. The shaft of the penis had a hard circumferentially indurated prepuce pulled slightly back over the glans, but it could not be retracted easily. The prepuce was non-fluctuant and nontender. There was involvement of the skin on the ventral shaft of the penis up to the midshaft; otherwise the remainder of the shaft was normal.

The patient supplied a vial of yellow oil that had been used in his injections. Upon analysis of micro-distillates of the oil using Fourier-transform infrared spectroscopy and x-ray fluorescence spectrometry, it was determined to be composed primarily of saturated,

**Author Affiliations:** Marshfield Clinic–Wausau Center, Wausau, Wis (Zickerman); Marshfield Clinic–Weston Center, Weston, Wis (Ratanawong).

**Author Correspondence:** Philip M. Zickerman, MD, Department of Urology, Marshfield Clinic–Wausau Center, 2727 Plaza Dr W3C, Wausau, WI 54401; phone 715.847.3351; fax 715.847.3045; e-mail zickerman.philip@marshfieldclinic.org.

straight-chain, 25 to 35 carbon, hydrocarbons (i.e., paraffin oil).<sup>22,23</sup> The only minor component was a volatile oil consistent with Ylang-Ylang oil,<sup>24</sup> commonly used as a soothing fragrance in aromatherapy to combat anxiety, high blood pressure, intestinal problems, sexual dysfunction, and stress. Although no histopathological examination was conducted, it was believed that the patient's phimosis was caused by a significant reaction to an injection of paraffin oil (i.e., penile paraffinoma).

Surgical excision was recommended, and in consultation with a plastic surgeon, it was determined that skin grafting would likely be required. The patient was resistant to the idea of aggressive therapy, and although he remained in the area and sought treatment for unrelated conditions, he has not sought further treatment for his phimosis.

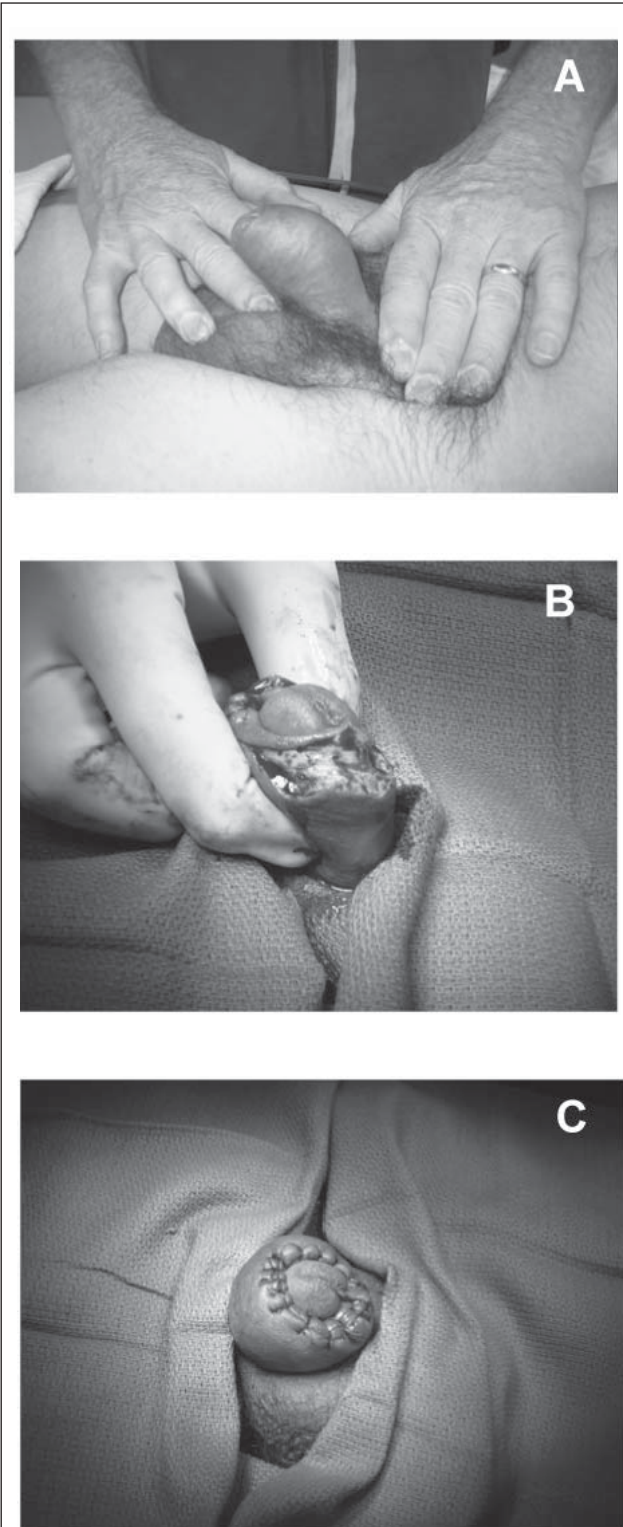
#### Case 2

A 44-year-old Hmong male was referred for evaluation of erectile dysfunction and foreskin symptoms. Reportedly, in an attempt to improve his erections, the patient had purchased an unknown "medication" on the black market and had injected it directly into his foreskin. Thereafter, the foreskin had swollen, thickened, and turned ruddy. He was unable to retract his foreskin to fully expose the glans penis, and he experienced difficulty in urinating and obtaining an erection.

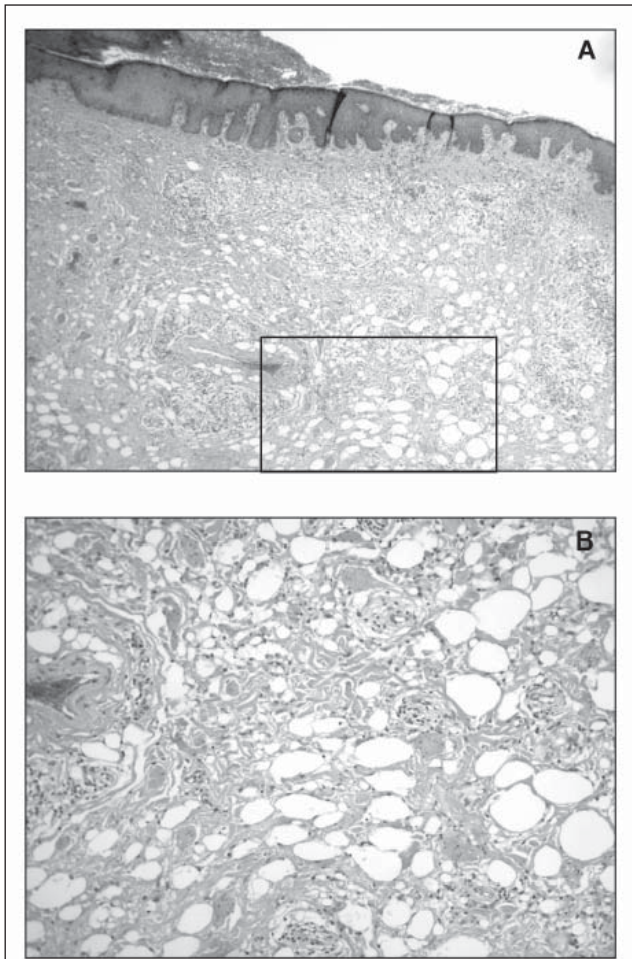
Upon genitourinary examination, the external genitalia appeared normal with an uncircumcised penis. The distal  $\frac{3}{4}$  of the penile shaft appeared thickened and ruddy (Figure 1A). The foreskin could not be retracted, but the area was not painful or erythematous. The glans itself could be observed through the tip of the foreskin. The meatus was in the normal position with no discharge. The testes were descended bilaterally and were normal in size and consistency. It was concluded that the patient's phimosis was caused by a reaction to the injected "medication" he purchased on the black market.

The patient freely consented to a circumcision but with the understanding that not all of the thickened foreskin would be removed. His glans was to be fully exposed to prevent inhibition of erections and urinary function. A prior low serum testosterone indicated that additional therapy might be required after circumcision, although his current testosterone level was within normal limits.

Under general anesthesia, a dorsal foreskin slit was created with some difficulty in cutting noted, and a small ventral slit was made. Two segments of foreskin were removed in a semicircular direction. The involved



**Figure 1.** (A) The distal  $\frac{3}{4}$  of the penile shaft appeared thickened and ruddy. (B) The involved foreskin was approximately 1 cm thick and fibrosis extended from the tip to close to the base encompassing approximately 95% of the entire foreskin. (C) The foreskin was reapproximated to expose the glans.



**Figure 2.** (A) Subcutaneous tissue with extensive fatty deposits and granulomatous reaction. (B) Magnification of boxed area.

foreskin was approximately 1 cm thick, and fibrosis extended from the tip to close to the base encompassing approximately 95% of the entire foreskin (Figure 1B). No purulence or infected pockets were noted. The foreskin was reapproximated to expose the glans. At the end of the procedure, it was dubious as to whether the foreskin would recover (Figure 1C).

Fourteen days post-surgery, the circumcision incision was intact with a slight breakdown toward the frenulum aspect of the foreskin. A thickened, infiltrative fibrotic process was still present. The patient was referred to a plastic surgeon to determine whether complete foreskin excision with a graft would be required.

Six weeks later, the patient presented complaining of a fibrotic mass just proximal to the ventral surface of the glans penis. The mass measured approximately 4 x 4 cm. Other fibroids, cords, and chronic edema of the cutaneous tissues were present, but the patient elected not to address these. He requested excision of the fibrotic tis-

sue at the ventral surface of the penis at the base of the glans. It was advised that the skin be elevated to remove the fibrotic mass at the dorsolateral aspect as well, but he did not wish to do so. He was informed that scarring may result that may eventually require excision and skin grafting.

Upon operation, a Foley catheter was placed to aid in identification of the urethra. A transverse elliptical incision was made, removing the overlying skin and subcutaneous tissue along with the extensive fibrotic mass. The excision was made just proximal to the ventral portion of the glans penis. The mass extended deeply into the subcutaneous tissue and continued both circumferentially and proximally, but this was not removed at the request of the patient. The patient tolerated the procedure well. Histopathology revealed subcutaneous tissue with extensive fatty deposits and granulomatous reaction (Figure 2).

Fifteen months later, the patient presented with swelling at the dorsum and further fibrosis at the left lateral aspect of the penis shaft that were bothersome to him, and he was requesting that more of this be removed. The ventral aspect of the previous excision had healed nicely, and there was no evidence of infection. The operation proceeded without complication, and there was minimal edema on follow-up 6 days later. The patient was subsequently treated with testosterone (5 g daily) and sildenafil citrate (50 mg as needed) to address his continuing concerns with erectile dysfunction and libido.

### Case 3

A 36-year-old male Hmong patient with 16 years of education and 8 children who had been married for 17 years was referred from the walk-in clinic. He was in no acute distress. Approximately 1 month previously, while in Minneapolis, he injected his penis with a Chinese herbal medicine to obtain an erection. This injection caused swelling of the foreskin to the point that it could not be retracted, and he reported discomfort with erection. He had no history of venereal disease, renal stones, genitourinary infection, or genitourinary instrumentation and had not undergone a vasectomy. He reported no genitourinary or outlet obstruction symptoms, dysuria, hematuria, or blood in his ejaculate.

Upon genital examination, the foreskin of his penis could not be retracted. A brawniness of the foreskin existed circumferentially and extended somewhat onto the distal shaft of the penis; however, there was no evidence of infection or hematoma. It was concluded that this condition was caused by injection of the Chinese herbal medicine and would require an extended surgical circumcision with plastic surgery consultation.

The surgery was discussed at length with the patient and his wife. Initially the wife insisted on a dorsal slit with the least amount of skin removed as possible, but it was explained that this would not remove the indurated area and would leave a large amount of redundant skin hanging in the ventral aspect. After further discussion of the procedure, indications, and risks, the patient and his wife agreed to the surgery.

In surgery, both partial dorsal and ventral slits were made down the foreskin, and the skin was excised circumferentially. About an inch of circumferential indurated tissue distal to the circumcision was left to avoid foreshortening of the penis. The margins were re-approximated to resolve the phimosis.

At follow-up, the patient experienced no significant bleeding or voiding problems, and the phimosis was resolved.

## DISCUSSION

Since the time that these 3 patients were evaluated and treated, others have been seen with similar histories and symptoms. Several elements of these cases are noteworthy. First, in all, the injected materials were obtained surreptitiously within the United States. These are not cases of Southeast Asian refugees arriving with preexisting conditions. How widespread this practice is among Asians within this country has not yet been reported.

Secondly, most of the reported cases in the literature have involved the injection of oils into the scrotal sacs and penile shaft in addition to the foreskin. Our cases evidently involved the foreskin only, with some spread of the granulomatous reaction proximally. The consequences, regardless of injection site, are the same, however. Involved tissues become hard, indurated, and semi-mobile. In some cases, the lesions can become ulcerated and purulent. Histologically, granulomatous tissue develops with numerous fat laminae, scattered fibrous tissue, and scattered chronic inflammatory cells.

Finally, the reported treatment for this condition has been extensive excision, often using scrotal skin as a graft source.<sup>8,25,26</sup> Our Hmong patients were reticent to remove anything but the most problematic tissues at the time. In these cases, other less radical approaches may be appropriate.<sup>27,28</sup> It has been reported that the Hmong believe it is not good to undergo surgery. They believe their souls may become frightened and leave the body during the surgery or that the surgery will cause them to be reincarnated with less than a complete body.<sup>29</sup> Similarly, circumcision is not practiced among the Hmong.<sup>30</sup> Interestingly, the Hmong do not believe in placing anything into the body because they will be

burdened with carrying a foreign object inside them when reincarnated.<sup>30</sup> However, this belief evidently does not extend to the injection of oils to address problems of erectile dysfunction or libido.

It is not uncommon for men of Southeast Asia to inject paraffin, mineral oils, liquid silicone, petrolatum, or other viscous materials into the penile shaft to increase its size, to correct erectile dysfunction, or to satisfy the sexual partner.<sup>2,12-14</sup> In reports emanating from Southeast Asian medical facilities, the mean ages of a series of Thai and Korean patients ranged from 28.9 years at presentation to 39.6 years.<sup>12-14</sup> Our patients' ages spanned the upper end of this age range.

Injections commonly result in extensive foreign body granulomatous and fibrotic reactions, varying with the purity and nature of the injected materials.<sup>31</sup> The resulting syndrome has been variously referred to as penile oleogranuloma, sclerosing lipogranuloma, or penile paraffinoma.<sup>5,26</sup> In severe cases, this ultimately leads to disfigurement, chronic unhealed ulcers, painful erection, and an inability to perform sexual activities.<sup>32,33</sup> Typically, the only treatment is complete resection of the skin and as much infiltrated tissue as possible. Any incorporation into the corpus cavernosum or corpus spongiosum must remain. Bilateral scrotal flaps have been used successfully in skin grafting to accomplish both functional and cosmetic goals without major complications.<sup>12,14,34</sup> Typical durable skin grafting in these situations is not usually completely successful.<sup>35,36</sup>

Some literature has previously been published exploring problems faced in providing intercultural medical care and for the Hmong in particular.<sup>20,21,37-39</sup> Interventional practices at multisystem levels have been designed and applied successfully in meeting the needs of many cultures.<sup>40-42</sup> It behooves all practitioners within communities experiencing influxes of immigrants to become aware of various ethnic cultural practices and taboos and to attempt to provide the best interventions possible without violating cultural, religious, and legal lines.<sup>43,44</sup> Many Hmong have lived in the United States for decades, and the young are becoming more accepting of Western medical procedures, but as more refugees continue to arrive, health care professionals should be prepared to encounter new and unusual presentations that require culturally sensitive treatment approaches.

**Acknowledgments:** Thanks to Marshfield Clinic Research Foundation for providing assistance in the preparation of this manuscript through the services of Linda Weis, Alice Stargardt, and Jennifer Hayes.

**Funding/Support:** None declared.

**Financial Disclosures:** None declared.

## REFERENCES

1. Odintsov BP, Panikratov KD, Patsanovskii AG. The surgical treatment of penile oleogranulomas. *Urol Nefrol (Mosk)*. 1991;(6):46-49.
2. Behar TA, Anderson EE, Barwick WJ, Mohler JL. Sclerosing lipogranulomatosis: a case report of scrotal injection of automobile transmission fluid and literature review of subcutaneous injection of oils. *Plast Reconstr Surg*. 1993;91(2):352-361.
3. Goriunov VG, Kudriavtsev luV, Krendel' BM, Amazaspian TZ. The etiology and pathogenesis of penile oleogranulomas. *Urol Nefrol (Mosk)*. 1994;(1):51-54.
4. Wassermann RJ, Greenwald DP. Debilitating silicone granuloma of the penis and scrotum. *Ann Plast Surg*. 1995;35(5):505-509.
5. Gfesser M, Worret WI. Paraffinoma of the penis. *Hautarzt*. 1996;47(9):705-707.
6. Thomas P, Boussuges A, Gainnier M, et al. Fat embolism after intrapenile injection of sweet almond oil. *Rev Mal Respir*. 1998;15(3):307-308.
7. Garcia Diez F, Izquierdo Garcia FM, Beneitez Alvarez ME, et al. Penile silicone granuloma. *Arch Esp Urol*. 2005;58(5):457-460.
8. Scholten E, Nanhekhan LV, Oudit D, Hage JJ. Scrotal and penile reconstruction after massive self-injection of liquid paraffin and petroleum jelly. *Plast Reconstr Surg*. 2005;115(7):2168-2169.
9. Hohaus K, Bley B, Kostler E, Schonlebe J, Wollina U. Mineral oil granuloma of the penis. *J Eur Acad Dermatol Venereol*. 2003;17(5):585-587.
10. Al-Khalil N, Panchev P, Tsvetkov M, Simeonov P, Mladenov D. A case of penis self-injection of liquid paraffin—operative treatment and results. *Khirurgiia (Sofia)*. 2004;60(3):65-66.
11. Santos P, Chaveiro A, Nunes G, Fonseca J, Cardoso J. Penile paraffinoma. *J Eur Acad Dermatol Venereol*. 2003;17(5):583-584.
12. Lee T, Choi HR, Lee YT, Lee YH. Paraffinoma of the penis. *Yonsei Med J*. 1994;35(3):344-348.
13. Wiwanitkit V. Penile injection of foreign bodies in eight Thai patients. *Sex Transm Infect*. 2004;80(6):546.
14. Jindarak S, Angspatt A, Loyvirat R, Chokrungravanont P, Siriwan P. Bilateral scrotal flaps: a skin restoration for penile paraffinoma. *J Med Assoc Thai*. 2005;88 (Suppl 4):S70-S73.
15. Ronningen BJ. Estimates of selected immigrant populations in Minnesota: 2004. Available at: [www.demography.state.mn.us/PopNotes/EvaluatingEstimates.pdf](http://www.demography.state.mn.us/PopNotes/EvaluatingEstimates.pdf). Accessed July 20, 2007.
16. The Hmong migration. Available at: [www.wisinfo.com/legacy/thailand/images/thailandmap.pdf](http://www.wisinfo.com/legacy/thailand/images/thailandmap.pdf). Accessed July 20, 2007.
17. Wisconsin Department of Workforce Development. Governor Doyle announces \$500,000 grant for refugee resettlement federal aid for Hmong resettlement now almost \$2 million. Available at: [www.dwd.state.wi.us/dwd/newsreleases/2005/100305\\_hmong\\_aid\\_500k.htm](http://www.dwd.state.wi.us/dwd/newsreleases/2005/100305_hmong_aid_500k.htm). Accessed July 20, 2007.
18. Sheehan E. "GREENS" Hmong gardens, farms and land ownership in America: constructing environment and identity in the Carolinas. Available at: <http://home.vicnet.net.au/~lao/laostudy/garden.htm>. Accessed July 20, 2007.
19. Southeast Asia Resource Action Center (SEARAC). Southeast Asian American Statistical Profile. Available at: [www.searac.org/seastatprofilemay04.pdf](http://www.searac.org/seastatprofilemay04.pdf). Accessed July 20, 2007.
20. Waldemar C. St. Paul physicians readying for surge of Hmong immigrants. *Minn Med*. 2004;87(8):10.
21. Tran HL. California Hmong refugee resettlement. Available at: [www.apiahf.org/policy/healthaccess/20041116testimony\\_hmong\\_resettlement.htm](http://www.apiahf.org/policy/healthaccess/20041116testimony_hmong_resettlement.htm). Accessed July 20, 2007.
22. Bories GF, Tulliez JE. A versatile method for the determination of normal paraffins in foods. *J Sci Food Agric*. 1977;28(11):996-999.
23. Simal-Gandara J, Sarria-Vadal M, Rijk R. Determination of paraffins in food simulants and packaging materials by liquid chromatography with evaporative mass detection and identification of paraffin type by liquid chromatography/gas chromatography and Fourier transform infrared spectroscopy. *J AOAC Int*. 2000;83(2):311-319.
24. Olivero J, Gracia T, Payares P. Molecular structure and gas chromatographic retention behavior of the components of Ylang-Ylang oil. *J Pharm Sci*. 1997;86(5):625-630.
25. Cohen JL, Keoleian CM, Krull EA. Penile paraffinoma: self-injection with mineral oil. *J Am Acad Dermatol*. 2002;47(5 Suppl):S251-S253.
26. Steffens J, Kosharsky B, Hiebl R, Schonberger B, Rottger P, Loening S. Paraffinoma of the external genitalia after autoinjection of vaseline. *Eur Urol*. 2000;38(6):778-781.
27. Ohjimi H, Ogata K, Ohjimi T. A new method for the relief of adult phimosis. *J Urol*. 1995;153(5):1607-1609.
28. Akkus E, Iscimen A, Tasli L, Hattat H. Paraffinoma and ulcer of the external genitalia after self-injection of Vaseline. *J Sex Med*. 2006;3(1):170-172.
29. Her C, Culhane-Pera KA. Culturally responsive care for Hmong patients. collaboration is a key treatment component. *Postgrad Med*. 2004;116(6):39-42, 45-46.
30. Children's Hospitals and Clinics of Minnesota. Hmong culture and medical traditions. Available at: <http://xpedio02.childrenshc.org/stellent/groups/public/@xcp/@web/@clinicsanddepts/documents/policyreferenceprocedure/web025019.asp>. Last modified 08/25/2003. Accessed July 20, 2007.
31. Oertel YC, Johnson FB. Sclerosing lipogranuloma of male genitalia. review of 23 cases. *Arch Pathol Lab Med*. 1977;101(6):321-326.
32. Rintala A. Ulcerating paraffinoma. *Ann Chir Gynaecol*. 1976;65(5):356-360.
33. Goldwyn RM. The paraffin story. *Plast Reconstr Surg*. 1980;65(4):517-524.
34. Jeong JH, Shin HJ, Woo SH, Seul JH. A new repair technique for penile paraffinoma: bilateral scrotal flaps. *Ann Plast Surg*. 1996;37(4):386-393.
35. McAninch JW. Management of genital skin loss. *Urol Clin North Am*. 1989;16(2):387-397.
36. Kendall AR, Karafin L. Repair of the denuded penis. *J Urol*. 1967;98(4):484-486.
37. Sung CL. Asian patients' distrust of western medical care: one perspective. *Mt Sinai J Med*. 1999;66(4):259-261.
38. Her C, Culhane-Pera KA. Culturally responsive care for Hmong patients. collaboration is a key treatment component. *Postgrad Med*. 2004;116(6):39-42, 45-46.
39. Sperstad RA, Werner JS. Coming to the cultural "in-between": nursing insights from a Hmong birth case study. *J Obstet Gynecol Neonatal Nurs*. 2005;34(6):682-688.
40. Keller LO, Strohschein S, Lia-Hoagberg B, Schaffer MA. Population-based public health interventions: practice-based and evidence-supported. part I. *Public Health Nurs*. 2004;21(5):453-468.
41. Keller LO, Strohschein S, Schaffer MA, Lia-Hoagberg B. Population-based public health interventions: innovations in practice, teaching, and management. part II. *Public Health Nurs*. 2004;21(5):469-487.
42. Tembreull CL, Schaffer MA. The intervention of outreach: best practices. *Public Health Nurs*. 2005;22(4):347-353.
43. Like RC. Culturally competent family medicine: transforming clinical practice and ourselves. *Am Fam Physician*. 2005;72(11):2189-2190.
44. Juckett G. Cross-cultural medicine. *Am Fam Physician*. 2005;72(11):2267-2274.

# Wisconsin Medical Journal

The mission of the *Wisconsin Medical Journal* is to provide a vehicle for professional communication and continuing education of Wisconsin physicians.

The *Wisconsin Medical Journal* (ISSN 1098-1861) is the official publication of the Wisconsin Medical Society and is devoted to the interests of the medical profession and health care in Wisconsin. The managing editor is responsible for overseeing the production, business operation and contents of the *Wisconsin Medical Journal*. The editorial board, chaired by the medical editor, solicits and peer reviews all scientific articles; it does not screen public health, socioeconomic or organizational articles. Although letters to the editor are reviewed by the medical editor, all signed expressions of opinion belong to the author(s) for which neither the *Wisconsin Medical Journal* nor the Society take responsibility. The *Wisconsin Medical Journal* is indexed in Index Medicus, Hospital Literature Index and Cambridge Scientific Abstracts.

For reprints of this article, contact the *Wisconsin Medical Journal* at 866.442.3800 or e-mail [wmj@wismed.org](mailto:wmj@wismed.org).

© 2007 Wisconsin Medical Society