

Acute Thigh Compartment Syndrome Post Femoral Vein Catheterization: A Case Report

Mark W. Asplund, MD, FACS

ABSTRACT

This case report presents a previously unreported etiology of acute thigh compartment syndrome following ipsilateral femoral vein catheterization, including clinical results and a brief review of the literature.

INTRODUCTION

Acute thigh compartment syndrome is a rare event usually precipitated by trauma, severe ischemia/reperfusion injury, extreme overuse, burns, or compression. This report describes a case of thigh compartment syndrome as a complication of right heart venous catheterization for radiofrequency ablation of atrial arrhythmias.

METHODS AND RESULTS

A 53-year-old man presented 5 days after transvenous ablation of atrial arrhythmias through a right common femoral vein catheterization at an outside hospital. His past medical history was significant for atrial arrhythmias. He also had a right hipbone graft harvest site, an old tibia-fibula fracture to the right, and a right knee arthroplasty. He was on several medications, most notably subcutaneous Dalteparin twice a day and Warfarin, which were both started at the time of the ablation. He was taking 1 aspirin a day. Pre-ablation records and laboratory values were considered unreliable because they were done at an outside hospital. After his radiofrequency ablation, he did well and was converted to normal sinus rhythm.

The patient is a vigorous man who participated in outdoor activities, which he immediately resumed. Twenty-four to 36 hours prior to admission, which was 4 days after his ablation procedure, he developed progressive right groin pain and then right thigh pain. This

progressed to numbness in his foot and an inability to walk. He presented to an outside emergency department (ED) where duplex of the femoral artery and vein failed to show any evidence of hematoma, deep vein thrombosis, arterial compromise, or pseudoaneurysm. Pulses were normal distally. The patient was discharged on oral analgesics. However, 3 hours later he sought care in our ED for progressive pain. A duplex was repeated with the same findings. The patient was again sent home with normal pulses, neurologically intact, and no specific diagnosis. However, after being discharged, he immediately returned from the parking lot unable to bear weight on his leg due to excruciating thigh pain and now-progressive paralysis. He returned to the ED and vascular surgery was consulted.

Examination at that time showed a pulse of 110, blood pressure of 140/80, and in sinus rhythm. There was a good Doppler pulse to the right foot. However, his foot now was becoming blue, somewhat edematous, and anesthetic. His thigh compartments were rock-hard anteriorly and posteriorly and exquisitely tender. His partial thromboplastin time (PTT) was 52, international normalized ratio (INR) was 1.62, hemoglobin was 9, and his potassium was 4. An immediate groin and thigh exploration was recommended for presumed acute hemorrhage into the thigh and groin.

The groin was explored under general anesthesia, and the femoral artery and vein were found to be normal-appearing with some perivenous edema and staining of the tissues, but no significant hematoma. The incision was carried down into the thigh, and edema seemed to be pushing the tissues from below upward as we continued down. The patient was deemed to have thigh compartment syndrome and, therefore, a complete fasciotomy was performed by both a lateral and medial approach to decompress the anterior, posterior, and medial thigh compartments. All compartments were hypertensive as evidenced by extreme bulging of the very edematous muscles, but the pressure posteriorly and laterally was

Author Affiliation: Surgical Associates, SC, Wausau, Wis.
Corresponding Author: Mark W. Asplund, MD, Surgical Associates, SC, 2400 Pine Ridge Blvd, Wausau, WI 54401; phone 715.847.2022; fax 715.847.2775; e-mail Marka@aspirus.org.

so high that fluid tinged with blood sprayed out of the compartment 2-3 meters. The muscles protruded and we were unable to close the skin incisions (Figure 1). There was some bloodstaining but no marked hemorrhage or hematoma to the tissues. The fasciotomy was continued into the gluteal region superiorly, but this did not appear to be involved. The wounds were left open, and all anticoagulation stopped.

Postoperatively, the patient experienced immediate relief of all symptoms, and all neurologic function returned to the foot except for a moderate foot drop. His postoperative course was complicated by bleeding in the incisions and a return of his atrial fibrillation. The wounds necessitated plastic surgery closure approximately 1 week postoperatively. One year later, the patient has complete use of his right leg with no long-term sequelae.

DISCUSSION

Acute thigh compartment syndrome is a rare event and is typically caused by trauma, usually involving a femur fracture or severe contusion of the thigh.² Other etiologies include burns, severe ischemia/reperfusion injury, and extreme overuse. Rarely reported causes include cardiopulmonary bypass through the femoral artery and vein in a child.¹ There have been no previously reported cases caused by percutaneous puncture, either arterially or venous. This case involved only a venous puncture. The puncture was in the common femoral vein with no involvement of the profunda or superficial femoral vein.

This patient clearly had thigh compartment syndrome of the anterior, lateral, and posterior compartments, with an unknown cause. Of the known causes, ischemia/reperfusion was ruled out by the Duplex findings, normal pulses, and the operative findings. Likewise, deep vein thrombosis was ruled out by the Duplex findings and the operative findings. These are both known causes of thigh compartment syndrome.³⁻⁵ There was no significant hemorrhage or hematoma. The patient was anticoagulated, which certainly could have contributed to bleeding as the cause for the compartment syndrome. However, his coagulation parameters were not excessive, nor was there significant bleeding discovered by Duplex or at the time of exploration. The tissue fluid encountered was edema that was blood-tinged.

The author believes this patient's compartment syndrome was caused by a relative outflow obstruction of the venous system due to the catheterization and

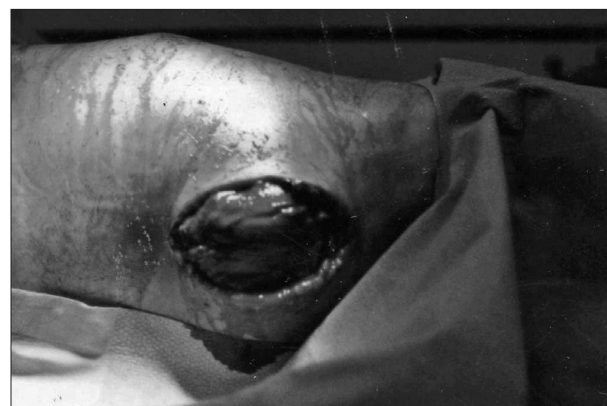

Figure 1. Medial approach to thigh decompression with bulging quadriceps and adductor muscles.

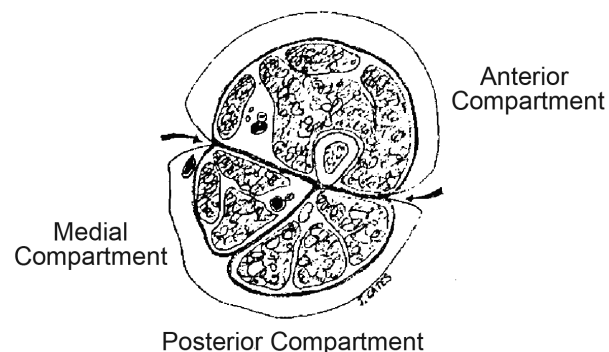


Figure 2. Anatomy of thigh compartments.⁶

perivenous edema and inflammation. This was significant in this patient because of his extreme vigorous activity, high pain threshold, and the fact that his leg compartments were somewhat rigid due to scarring from previous orthopedic injuries. This patient had a previous knee arthroplasty and a second large lateral thigh incision using the hipbone as a donor site for repair of a tibia-fibula fracture years ago. This then set up a vicious cycle where the rigid compartments became edematous due to exercise and relative venous obstruction causing more venous obstruction and more edema. This is a very unusual set of circumstances but is the only explanation for the patient's compartment syndrome, given the operative and Duplex findings.

Clinically, this patient presented with all the stigmata of thigh compartment syndrome with severe thigh pain, rock-hard thigh compartments on palpation, motor and neurologic dysfunction distally, and with complete relief of all his symptoms on the fasciotomy of the anterior, posterior, and lateral thigh compartments. This was particularly demonstrated by the force of the evacuation of the edema from the lateral approach (Figure 2).

CONCLUSION

This case is believed to be a previously unreported etiology of thigh compartment syndrome, successfully treated by fasciotomies. Previous orthopedic procedures to the thigh, vigorous activity, high pain threshold, and anticoagulation are believed to have led to acute thigh compartment syndrome. Contributing factors include recent venous catheterization with a relative venous obstruction. Health care professionals must be aware of such an event in the future.

Funding/Support: None declared.

Financial Disclosures: None declared.

REFERENCES

1. Williams PH, Bhatnager NK, Wiseheart JD. Compartment syndrome in a 5-year-old child following femoral cannulation for cardiopulmonary bypass. *Eur J Cardiothorac Surg.* 1989;113:81-89.
2. Viegas SF. Acute compartment syndrome in the thigh: a case report and review of the literature. *Clin Ortho Relat Res.* 1988;234:232-234.
3. Dennis C. Disaster following femoral vein ligation for thrombophlebitis. *Surgery.* 1945;17:264-269.
4. Shah P. Compartment syndrome in combined arterial and venous injuries of the lower extremity. *Am J Trauma.* 1989;158:136-141.
5. Best I, Bumpers H. Thigh compartment syndrome after acute ischemia. *Am Surg.* 2002;68:996-998.
6. Schwartz JT, Brumback RJ, Lakatos R, Poka A, Bathon GH, Burgess AR. Acute compartment syndrome of the thigh; a spectrum of injury. *J Bone Joint Surg.* 1989;71:392-400.

Wisconsin Medical Journal

The mission of the *Wisconsin Medical Journal* is to provide a vehicle for professional communication and continuing education of Wisconsin physicians.

The *Wisconsin Medical Journal* (ISSN 1098-1861) is the official publication of the Wisconsin Medical Society and is devoted to the interests of the medical profession and health care in Wisconsin. The managing editor is responsible for overseeing the production, business operation and contents of *Wisconsin Medical Journal*. The editorial board, chaired by the medical editor, solicits and peer reviews all scientific articles; it does not screen public health, socioeconomic or organizational articles. Although letters to the editor are reviewed by the medical editor, all signed expressions of opinion belong to the author(s) for which neither the *Wisconsin Medical Journal* nor the Society take responsibility. The *Wisconsin Medical Journal* is indexed in Index Medicus, Hospital Literature Index and Cambridge Scientific Abstracts.

For reprints of this article, contact the *Wisconsin Medical Journal* at 866.442.3800 or e-mail wmj@wismed.org.

© 2008 Wisconsin Medical Society