

# A Case of Pityriasis Amiantacea with Rapid Response to Treatment

Gabrielle Mannino, MS; Cort McCaughey, MD; Erin Vanness, MD

## ABSTRACT

Pityriasis amiantacea is a rare cutaneous reaction pattern to various underlying inflammatory diseases of the scalp. The clinical findings are very characteristic but often under-recognized. This condition can lead to scarring alopecia, and can be refractory to conservative treatment. It is therefore important to recognize the condition so that appropriate treatment can be initiated promptly.

## INTRODUCTION

Pityriasis amiantacea (PA) is an inflammatory condition of the scalp that is described as thick, adherent, asbestos-like scales. The scale attaches in layers to both the scalp and hair shafts, and when removed can lead to temporary or scarring alopecia. Studies suggest that PA represents a reaction pattern of the scalp to various inflammatory diseases, the most common being seborrheic dermatitis, psoriasis, and tinea capitis. Recent literature has entertained the notion that concomitant *Staphylococcus aureus* also may contribute to the pathogenesis of PA.

## Case Presentation

A 25-year-old woman was seen in the dermatology clinic for evaluation of diffuse adherent scaly lesions on her scalp with associated hair loss. She had no evidence of cutaneous psoriatic plaques or characteristic nail changes to suggest psoriasis as an underlying cause. There was no evidence of fungal infection of the skin or nails and no discrete nummular areas of hair loss to suggest tinea capitis. She did claim a history of mild “dandruff,” which was suggestive of seborrheic dermatitis as the underlying etiology. She had been treated with over-the-counter shampoos containing tar and salicylic acid as well as desonide cream, all of which were minimally helpful.

• • •

**Author Affiliations:** University of Wisconsin School of Medicine and Public Health, Madison, Wis (Mannino, McCaughey, Vanness).

**Corresponding Author:** Gabrielle Mannino, MS, University of Wisconsin School of Medicine and Public Health, Department of Dermatology, 1 S Park St, 7th Fl, Madison, WI 53715; phone 608.287.2620; fax 608.287.2676; e-mail gmannino@wisc.edu.

Scalp exam revealed thick, adherent, asbestos-like scales, which were attached both to the scalp and to the proximal hair shafts (Figure 1). Hair casts were revealed on removal of hair, leaving a moist erythematous base. There were thin ill-defined erythematous plaques with overlying greasy scale underlying the more thick adherent scale, which was suggestive of seborrheic dermatitis (Figure 2).

In this case, the PA responded rapidly (near complete clearance within 2 weeks) to topical mineral oil under occlusion, daily salicylic acid shampoo, clobetasol solution twice daily, and a 2-week course of cephalexin. Treatment included a combination of previously reported successful treatment algorithms.

## DISCUSSION

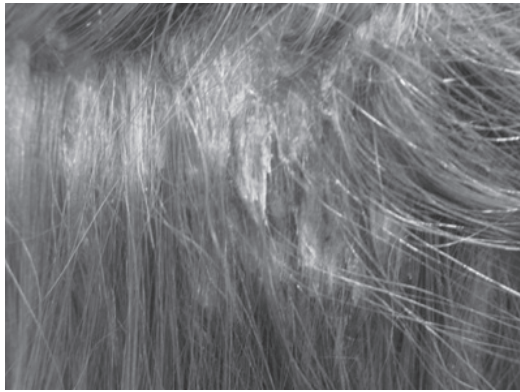
PA appears primarily to affect young adults and is more common in females.<sup>1</sup> The condition is easily diagnosed by its typical clinical appearance. Alopecia is a prominent feature of PA, but is temporary when early, appropriate treatment is initiated.<sup>2</sup>

Clinicians continue to be puzzled by the etiology of PA and have struggled to define the most appropriate treatment modality. The pathogenesis of PA is challenging because the scalp appears to react with a similar pattern to various inflammatory dermatoses. Scalp biopsy has revealed pathologic diagnoses that include seborrheic dermatitis, psoriasis, superficial pyogenic or fungal infections, lichen planus, lichen simplex chronicus, and atopic dermatitis.<sup>1,3</sup> Despite these disease associations, the mechanism of formation of the scale that defines PA is uncertain.

Knight isolated *S aureus* in 4 of 71 patients with PA, and Abdel-Hamid et al observed positive bacterial cultures in 83 of the 85 patients with this condition.<sup>1,4</sup> In these cases, *S aureus* was thought to most likely represent a secondary infection. In one more recent report, *S aureus* was isolated in the majority of patients with PA (81.3%) compared to the control group (3.1%). Moreover, all patients in this study responded quickly to a regimen that included systemic antibiotics as well as topical corticosteroids and coal tar.<sup>5</sup>

PA is notoriously treatment resistant and there are currently no specific treatment guidelines. It is agreed, however, that treatment

**Figure 1.** Scales Characteristic of Pityriasis Amiantacea



Examination of the scalp revealed thick adherent scales which were attached both to the scalp and to the proximal hair shafts.

**Figure 2.** Erythematous Plaques



Poorly defined erythematous plaques with greasy scale, suggestive of seborrheic dermatitis, underlie the more thickly adherent scale.

should target the underlying inflammatory condition; ie, seborrheic dermatitis, psoriasis, tinea, etc. Previous case reports/series have observed variable improvement with topical and systemic corticosteroids, keratolytics, and other immunosuppressants.<sup>6</sup> In more recent reports, treatment success was improved when more conventional treatments were combined with systemic antibiotics targeting *S aureus*. This favors the hypothesis that bacterial infection may play an important role in the pathogenesis of this condition.

## CONCLUSION

Without timely and effective treatment, PA may evolve into a chronic skin condition and may result in scarring alopecia. Therapy should be directed toward the underlying dermatosis. More recent literature suggests improved treatment success when combination anti-inflammatory and antibiotic treatment is initiated.

**Funding/Support:** None declared.

**Financial Disclosures:** None declared.

---

## REFERENCES

1. Abdel-Hamid IA, Salah AA, Moustafa YM, El-Labban AM. Pityriasis amiantacea: a clinical and etiopathologic study of 85 patients. *Int J Dermatol.* 2003;42:260-264.
2. Langtry JA, Ive FA. Pityriasis amiantacea, an unrecognized cause of scarring alopecia described in four patients. *Acta Derm Venereol.* 1991;71:352-353.
3. Verardino GC, Azulay-Abulafia L, Macedo PM, Jeunon T. Pityriasis amiantacea: clinical-dermatoscopic features and microscopy of hair tufts. *An Bras Dermatol.* 2012;87(1):142-145.
4. Knight AG. Pityriasis amiantacea: a clinical and histopathological investigation. *Clin Exp Dermatol.* 1977;2(2):137-143.
5. Shalev RM, Cohen AD, Medvedovsky E, Sashavinsky S, Tchetov T, Vardy DA. Pityriasis amiantacea associated with *Staphylococcus aureus* in Bedouin patients. *Microb Ecol Health Dis.* 2004;16(4):218-221.
6. Pham RK, Chan SC, Hsu S. Treatment of pityriasis amiantacea with infliximab. *Dermatol Online J.* 2009;15(12):13.

advancing the art & science of medicine in the midwest

**WMJ**

The mission of *WMJ* is to provide a vehicle for professional communication and continuing education for Midwest physicians and other health professionals.

*WMJ* (ISSN 1098-1861) is published by the Wisconsin Medical Society and is devoted to the interests of the medical profession and health care in the Midwest. The managing editor is responsible for overseeing the production, business operation and contents of the *WMJ*. The editorial board, chaired by the medical editor, solicits and peer reviews all scientific articles; it does not screen public health, socioeconomic, or organizational articles. Although letters to the editor are reviewed by the medical editor, all signed expressions of opinion belong to the author(s) for which neither *WMJ* nor the Wisconsin Medical Society take responsibility. *WMJ* is indexed in Index Medicus, Hospital Literature Index, and Cambridge Scientific Abstracts.

For reprints of this article, contact the *WMJ* at 866.442.3800 or e-mail [wmj@wismed.org](mailto:wmj@wismed.org).

© 2014 Wisconsin Medical Society